


# Tilapia major clinical signs (Sinais Jeral Moras ikan Nila)

Objektivu husi poster nee atu haforsa kapasidade sentru fini ikan, viveirus, hakiak ikan nain sira no servisu estensaun sira atu rekuneshe no relata moras ikan Nila. Asaun preventiva, hatene inisiu sinais klinika no intervensaun rapidu hanesan dalam ida diak liu atu halo jestaun ba moras animal aquatiku. Karik ita observa sinais klinika, atitude la normal, no ikan mate la hanesan bain-bain, kontaktu ofisial aquikultura atu relata no husu ajuda.



**Fish lethargic at surface and not feeding**

Ikan mai bee leten no lakohi han



**Eye exophthalmia/popeye**

Ikan matan bubu sai



**Eye endophthalmia/eye shrinkage**

Ikan matan kuak tama



**Eye opacification**

Ikan matan kleuk no mutin



**Skin erosions hemorrhagic lesion**

Ikan kulit at no mean



**Skin discoloration**

Mudansa kor ba kulit



**Open wounds**

Kulit naklosu, bubu sai



**Abdominal distension/swelling**

Kabun bubu



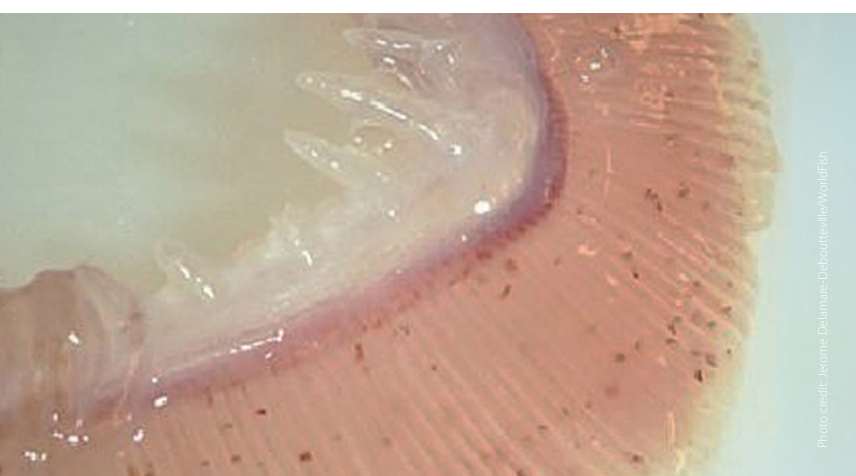
**Scale protrusion/detachment**

Kulit ikan naklosu sai



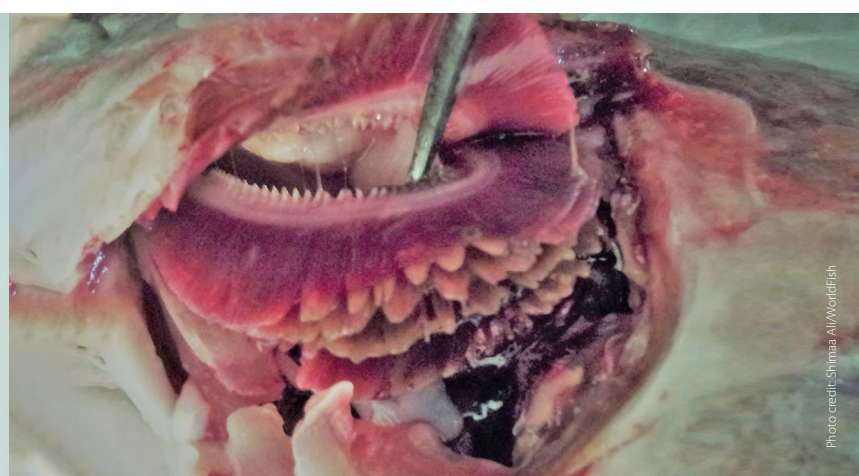
**Fish gasping air at the surface**

Ikan loke ibun no dada is iha bee leten




**Gill paleness (anemia)**

Guelra kamutis



**Gill rot**

Guelra dodok



**Fin rot/tail rot**

Kulit no ikun aat



**Swollen anus**

Kabun kidun bubu

This tilapia disease extension material and photographs were developed by the CGIAR Research Program on Fish Agri-Food Systems (FISH) led by WorldFish. It was produced as part of the WorldFish better management practice (BMP) resources to support sustainable and responsible tilapia farming. The translation into Tetum language and printing of this material were funded by the Partnership for Aquaculture Development in Timor-Leste Project from the New Zealand Aid Program.